



# Clinical Profile of Ocular Trauma at a Tertiary Care Hospital

**Anju Bhaskar <sup>a++\*</sup> and Rajiv Kumar Gupta <sup>b#</sup>**

<sup>a</sup> Department of Ophthalmology, Pt. Jawaharlal Nehru Memorial medical college, Raipur, Chhattisgarh, India.

<sup>b</sup> Department of Ophthalmology, RIO, RIMS, Ranchi, Jharkhand, India.

## **Authors' contributions**

*This work was carried out in collaboration between both authors. Both authors read and approved the final manuscript.*

## **Article Information**

DOI: <https://doi.org/10.9734/or/2024/v19i4431>

## **Open Peer Review History:**

This journal follows the Advanced Open Peer Review policy. Identity of the Reviewers, Editor(s) and additional Reviewers, peer review comments, different versions of the manuscript, comments of the editors, etc are available here: <https://www.sdiarticle5.com/review-history/119691>

**Original Research Article**

**Received: 03/05/2024**

**Accepted: 06/07/2024**

**Published: 10/07/2024**

## **ABSTRACT**

**Background:** Ocular trauma is preventable and one of the leading causes of ocular morbidity and blindness. Approximately 6 million people are blind from eye injuries, 2.3 million with bilateral visual impairment and 19 million with unilateral visual loss worldwide. In developing countries like ours the incidence of eye injuries is very high. This study has been conducted in the view of public health importance to provide information on magnitude, clinical and epidemiological profile of ocular injuries.

**Methods:** A hospital based, cross sectional observational study, conducted during September 2014 - March 2016 in tertiary care center in Jharkhand, all cases of ocular trauma were included in the study. Demographic profile (age, sex, locality, occupation), nature and cause of injury was recorded. Detailed ophthalmological examination including visual acuity, slit lamp examination,

<sup>++</sup> Assistant professor;

<sup>#</sup> Professor and HOD;

<sup>\*</sup>Corresponding author: E-mail: [dr.anjubhaskar@gmail.com](mailto:dr.anjubhaskar@gmail.com);

indirect ophthalmoscopy, B-scan, intraocular pressure measurement, gonioscopy, computed tomography brain with orbit, Magnetic Resonance Imaging, X-Ray were done in relevant cases.

**Results:** Total of 948 patients of ocular trauma were included. Most patients belong to the age group 21-40 years (60.87%), with mean age of  $29.79 \pm 16.47$  years. Males were affected more (73.52%) than females (26.47%). Closed globe injuries were more (75%) than open globe injuries (25%). Anterior segment was involved in (94.30%) and posterior segment in (8.86%). Work-related ocular injuries formed the commonest mode of injury (41.8%) followed by road traffic accident (30.37%).

**Conclusion:** Ocular trauma is one of the most common causes of unilateral blindness. Targeting groups most at risk with health education, providing effective eye protection and strict implementation of traffic rules may decrease the occurrence of ocular injuries.

*Keywords: Ocular trauma; anterior segment; open globe injury; closed globe injury; workplace.*

## 1. INTRODUCTION

“Ocular injury is an important cause of preventable and predominantly, monocular visual impairment and blindness” [1,2]. “As reported by WHO 55 million eye injuries causes restriction of daily activities, of which 1.6 million go blind every day” [3]. “Vats et al. have reported the prevalence of ocular trauma to be 2.4% of population in an urban city in India, 11.4% of these are blind” [4]. “Nearly 90% of this blindness can be prevented by relatively simple measures” [5]. “Despite its public health importance, there is relatively less population-based data on the magnitude and risk factors for ocular trauma, especially from developing countries. The incidence of eye injuries may be higher in developing countries” [6,7]. It is very important to understand the types of injury and clinical management required for them. As ocular trauma can be guarded against to a large extent, timely decisions are needed to prevent its consequences. Determining the risk factors would provide the basis to develop strategies for the management and prevention of ocular injuries. “These injuries can occur in almost any setting including recreational and sports related activities, work place, home, rural agriculture setting and road traffic accidents” [8]. Epidemiology of ocular trauma has been clearly studied in developed countries but there is limited data on severity, mode and outcome from developing countries [9]. This study is a small effort to bring information among the community regarding the different types of ocular trauma for its timely and prompt management.

## 2. METHODS

A prospective hospital-based cross sectional observation study was conducted at Regional Institute of Ophthalmology (RIO), Rajendra

Institute of Medical Sciences (RIMS), Ranchi, Jharkhand, September 2014- September 2016 after ethical clearance from the scientific committee. The ocular injuries were classified using the standardized international classification of ocular trauma, Birmingham Eye Trauma Terminology System (BETTS) which is one of the most widely accepted classification [9].

All the information was collected in a predesigned and pre-tested Performa. All ocular trauma patients of less than 7 days seen for the first time were included in the study. Patients with old cases of more than 7 days of ocular trauma and any other ocular pathology were excluded from the study. Written informed consent was taken from all the participant prior to study after explaining in patient's own language its gains and risks, and goals of the procedure. All participants were subjected to detailed clinical evaluation. Demographic data of the patient including name, age, sex, occupation, literacy, rural/urban, mode of injury, chief complaints, history of present illness, past history, treatment history was noted. General examination including assessment of conscious level, arterial pulse, blood pressure, respiratory rate was examined. Detailed ophthalmic examination of both eyes done, visual acuity noted using Snellen's acuity chart, abnormalities of orbit and orbital rim, extraocular movements were examined. Slit lamp examination done to assess eyebrow, lids, conjunctiva, sclera, cornea, anterior chamber, pupil, iris and lens. Investigations done in relevant cases, indirect ophthalmoscopy with 20D for fundus examination was done. Goldman applanation tonometry, B-SCAN ultrasonography, Optical Coherence Tomography done wherever possible, computed tomography, magnetic resonance imaging, X-Ray done in relevant cases.

### 3. RESULTS

A total of 948 patients of ocular trauma were seen in the tertiary eye care center, Rajendra institute of medical sciences, Ranchi from September 2014- September 2016. In present study 21-40 years age group is most commonly affected 577 eyes (60.87%). Males were affected more 697 eyes (73.52%) than females 251 eyes (26.47%). Closed globe injuries were more common 711 eyes (75%) than open globe injuries in 237 eyes (25%). Anterior segment was involved in 864 eyes (94.30%) and posterior segment in 84 eyes (8.86%). Work-related ocular injuries formed the commonest mode of injury 396 eyes (41.8%) followed by road traffic accident 288 eyes (30.37%). Open globe injuries

presented with poor visual acuity as compared to closed globe injuries.

**Age distribution:** Age ranged from 6 months to 80 years with mean of  $29.79 \pm 16.47$  years.

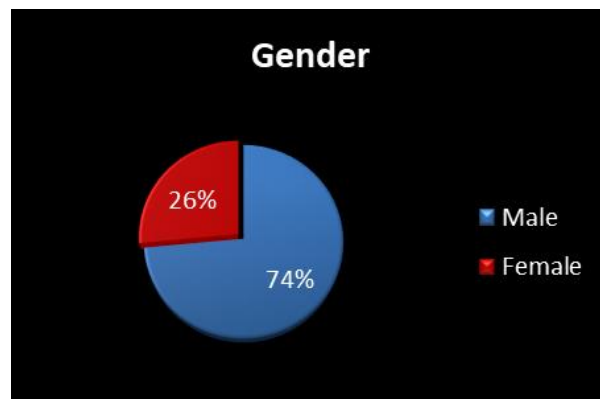
**Gender Distribution:** Male patients 697 (73.52%) were more as compared to female patients 251 (26.47) in the ratio of 2.8:1.

**Residence:** Most patients were from rural areas 695 (73.31%).

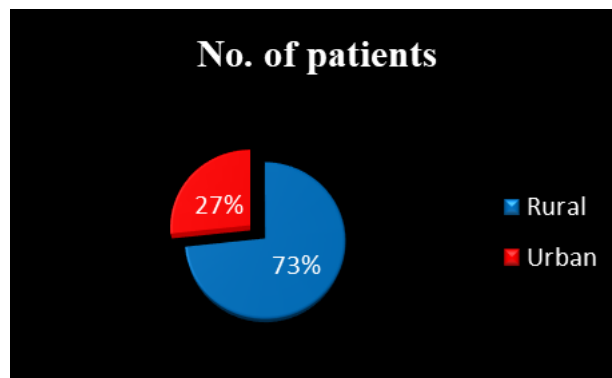
**Type of injury:** Most cases were closed globe injury 711(75%), rest were open globe injury 237(25%).

**Table 1. Age distribution**

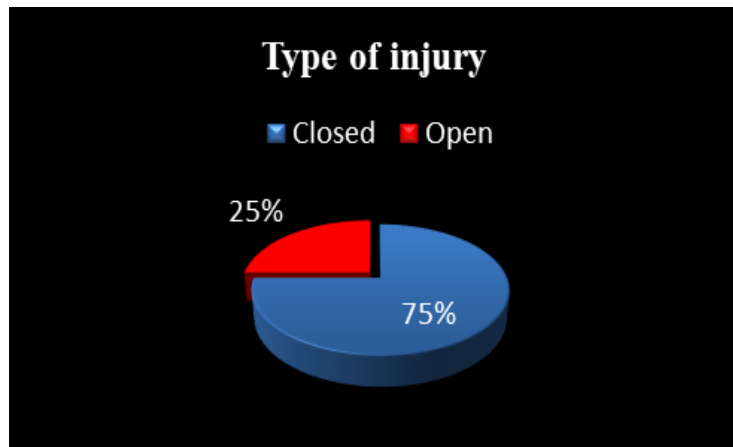
Age (years)	Frequency	Percent
0-20	123	12.98
21-40	577	60.87
41-60	172	18.14
>60	76	8.01
Total	948	100



**Graph. 1. Gender distribution**



**Graph 2. Residence distribution**



**Graph. 3. Type of injury**

**Mode of injury:** Most common mode of injury was found to be the Workplace 396(41.8%), followed by Road traffic accident 288(30.37%).

**Occupation:** Laborer group is most commonly involved (32.91%), followed by farmers (18.35%).

**Anterior Segment findings:** Most common finding is found to be corneal foreign body (30.80%) followed by corneal tear (18.14%).

**Posterior segment:** Most common posterior segment manifestation was found to be retinal detachment (3.97%).

**Other findings:** Many anterior segment findings were found to be in common also along with posterior segment involvement and with involvement of Lid and adnexa. Orbital wall fracture was found in 3 of the patients, along with other cranial nerve palsies oculomotor and trochlear nerve involvement.

**Objects causing ocular injury:** Amongst the objects causing ocular injury, the main culprits were wooden sticks and grass leaves.

**Visual acuity at presentation:** Visual acuity was found to be better in closed globe injury as compared to open globe injury.

**Table 2. Mode of injury**

Mode of injury	Frequency	Percent
Workplace	396	41.8
RTA	288	30.37
Domestic	111	11.70
Sports	81	8.54
Assault	72	7.6
Total	948	100

**Table 3. Occupation related to ocular trauma**

Occupation	Frequency	Percent
Laborer	290	30.6
Farmer	184	19.40
Student	89	9.4
Housewife	103	10.9
Industrial worker	60	6.32
Others	222	23.41
Total	948	100

**Table 4. Anterior segment finding**

<b>Finding</b>	<b>Frequency</b>	<b>Percent</b>
Corneal foreign body	292	30.80
Conjunctival foreign body	16	1.68
Corneal tear	172	18.14
Scleral tear	75	7.91
Subconjunctival hemorrhage	72	7.59
Dislocated/ subluxated lens	6	0.63
Traumatic cataract	69	7.27
Hyphema	41	4.32
Corneal abrasion	80	8.43
Iris prolapse	8	0.84
Lid tear	138	14.56
IOFB	5	0.52

**Table 5. Posterior segment finding**

<b>Finding</b>	<b>Frequency</b>	<b>Percent</b>
Retinal detachment	36	3.79
Vitreous hemorrhage	23	2.42
Macular hole	17	1.79
Optic neuropathy	8	0.84

**Table 6. Other findings**

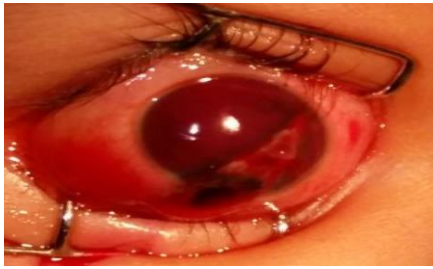<b>Finding</b>	<b>Frequency</b>
Corneal tear+ iris prolapse	7
Corneal tear+ scleral tear	9
Corneal tear+ IOFB	5
Corneal tear+ traumatic cataract	40
Sclera tear+ uveal tissue prolapse	1

**Table 7. Objects causing ocular injury**

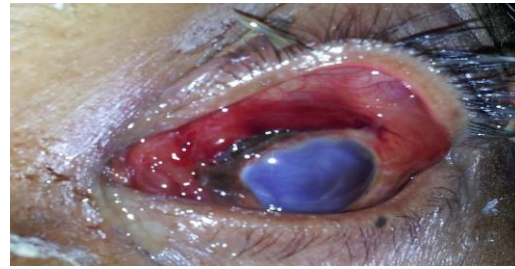<b>Objects</b>	<b>Open globe injury</b>	<b>Closed globe injury</b>	<b>Total</b>
Wooden stick	54	98	152
Animal	14	27	41
Thorn	25	12	37
Stone	31	87	118
Chemical	00	07	07
Cricket ball, bat, hockey stick	09	83	92
Sharp object (needle, spring, glass particle)	41	21	62
Iron rod	34	67	101
Tree branch	27	76	103
Leaf	00	81	81
Finger nail, fist, elbow, foot	02	82	84
Burn	00	12	12
Insect	00	58	58
<b>Total</b>	<b>237</b>	<b>711</b>	<b>948</b>

**Table 8. Visual acuity at presentation**

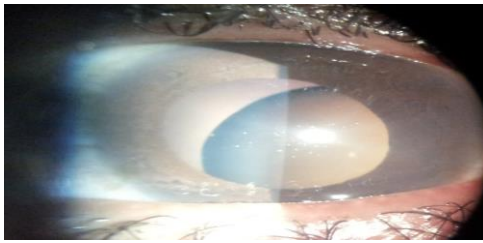
<b>Visual acuity</b>	<b>Frequency</b>	<b>Percent</b>
>6/60	548	57.80
6/60-HM	322	33.96
PL +ve	54	5.96
No PL	24	2.53
<b>Total</b>	<b>948</b>	<b>100</b>



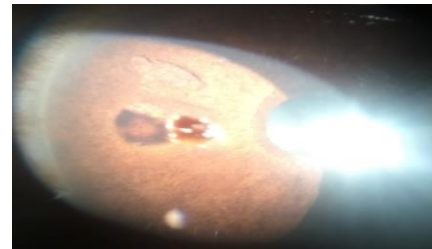
**Fig. 1. Corneal tear with hyphema**



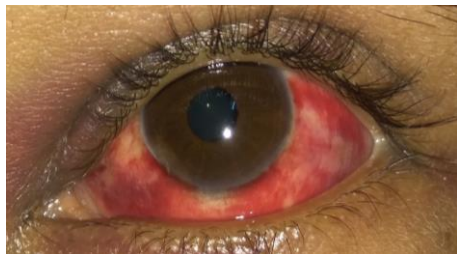**Fig. 2. Scleral tear with uveal tissue prolapse**



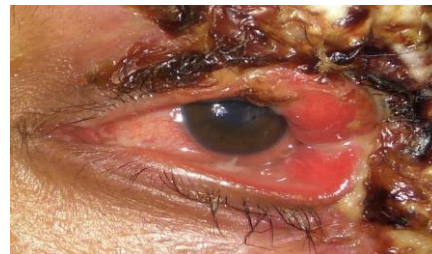**Fig. 3. Subluxated lens**



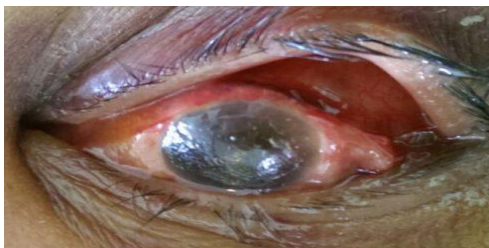
**Fig. 4. Corneal foreign body**



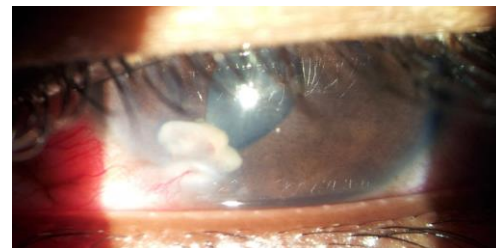
**Fig. 5. Subconjunctival hemorrhage**



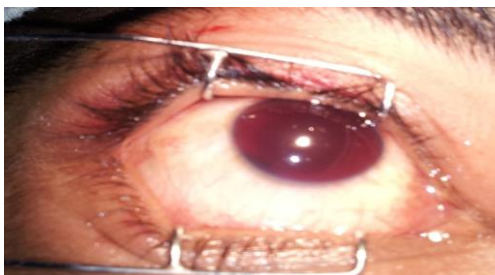
**Fig. 6. Burn injury- corneal abrasion, ectropion**



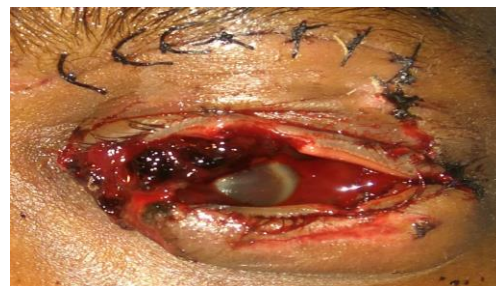**Fig. 7. Scleral tear**



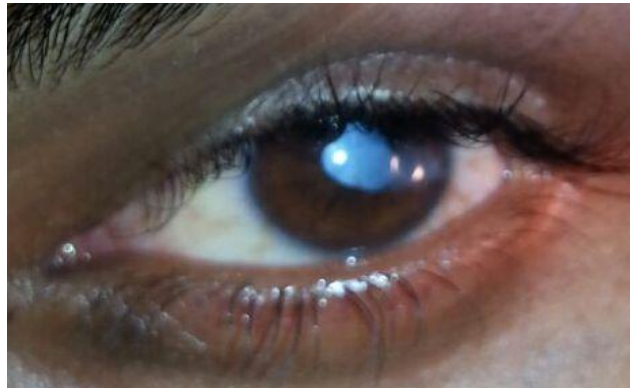**Fig. 8. Intraocular foreign body**



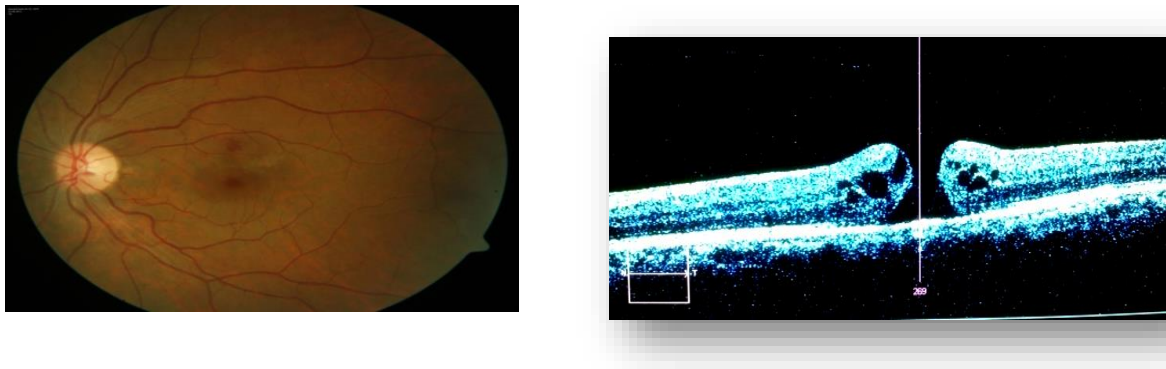
**Fig. 9. Hyphema following blunt trauma**



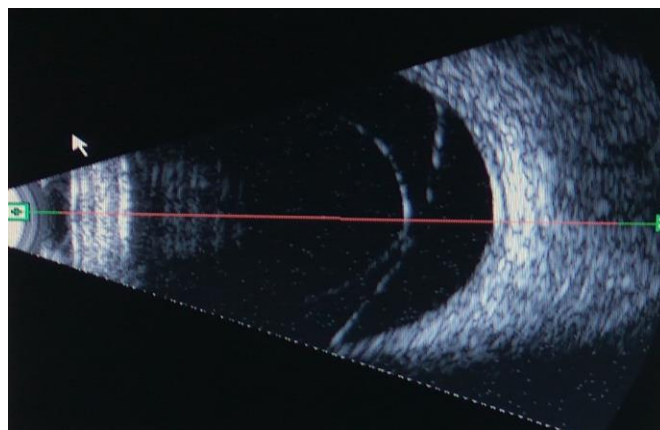
**Fig. 10. Lid tear, corneal tear with uveal tissue prolapsed**



**Fig. 11. Traumatic cataract**



**Fig. 12. Macular hole**



**Fig. 13. B-scan of retinal detachment**

#### **4. DISCUSSION**

“Worldwide ocular injuries constitute a major cause of visual morbidity and blindness, with significant impact on daily activity. It is an important cause of preventable, unilateral loss of vision, particularly in developing countries” [10]. “Young adult males carry the highest incidence of ocular injuries” [11]. “In developed countries ocular trauma also often shows bimodal peak

with second peak in old age’ [12,13]. In our study, there was increased incidence of ocular injuries in young adults in the age group 21-40 years (60.87%). This is in correlation with study done by (Dandona et al) [14] Male patients were more common (73.52%) as compared to females (26.47%) with M:F ratio of 2.8:1. Other studies revealed a M:F ratio of 4:1 (Babar et al.) [15], 3:1 (Jahangir et al) [16] and 5.25:1 (Arfat MY et al) [17]. Govind Singh Tityal et al. [18] in their study

noted 76.01% are males and 23.99% are females with ocular injury. S Vats, GVS Murthy et al. [19] in their study noted a significantly higher no. of males affected the mean age of incidence is 24.2 yrs. D.N. Prakash et al. [20] studied a total of 90 cases of whom 65.5% were male. In the current study men were injured more in work place and road traffic accidents while women were injured more at home.

In our study workplace injuries were found to be most common mode of injury (41.8%). Work related injuries were also reported to be the commonest cause of eye injury in other studies [21-22]. Sports related injury were seen in (8.54%). "In recent times sports related injuries and injuries at home has been recognized as the common location for ocular injury in United States of America and developed countries" [23,24]. In current study road traffic accidents related injuries occurred in 30.37% patients and chemical injuries were seen in 7 eyes. Injuries due to assault (7.6%) were seen more common in female population (60 eyes). Of the total workplace related injuries 30.59% occurred in labors and 19.40% occurred in farmers. Nirmalan, Katz et al. [25] noted high no. of cases in laborer. S. Krishnaiah et al. [26] also noted the same.

In the current study closed globe injuries (711 cases, 75%) were higher as compared to open globe injuries (237 cases, 25%). This finding correlates well with Rajendra P. Maurya et al. [27].

"We found the commonest object causing open globe injury was a wooden stick (22.78%), These findings correlate well with studies" done by Umesh et al. [28] "The commonest object causing closed globe injury in 98 patients was a wooden stick (13.78%) followed by stone (12.23%). Krishnan et al reported similar findings in their study" [29]. The majority of the patients in our study presented with only anterior segment involvement (91.14%). 2.33% patients in our study had both anterior as well as posterior segment involvement. In the current study anterior segment was most frequently involved, corneal foreign body being the most common (30.80%) followed by corneal tear (18.14%) and lid tear (14.56%).

"Patients with open globe injury, presented with a corneal tear with or without iris prolapsed, traumatic cataract, corneoscleral tear, foreign body in anterior chamber. Patients having closed

globe injury presented with alkali burn, full thickness upper or lower lid tear, conjunctival foreign body, subconjunctival hemorrhage, corneal lamellar laceration, corneal ulcer with hypopyon, corneal abrasions, hyphema, traumatic cataract, macular edema, vitreous hemorrhage, retinal detachment. These findings coincide well with the findings" of Bigar F, Ariturk et al and Thompson et al. [30-31].

"In our study, blunt injuries predominate (89.24%). In only 10.76%, injury was caused by sharp objects. This finding was consistent" with those of MacEwen et al. [32] and contrary to the study of Jahangir et al. [33] and Fasih et al. [34] in which most common source of injury was sharp objects.

A large proportion of the patients were from rural areas (73.31%), and this reflects a greater exposure to occupations in rural areas as opposed in urban areas (26.69%).

"Visual impairment due to ocular injury depends on the extent of damage, and the type of injury. Penetrating injuries carry a poorer prognosis than closed globe injuries" [35-36]. In the current series 57.80% (548 eyes) had mild to moderate visual impairment (visual acuity >6/60) and 42.2% (400 eyes) suffered severe visual loss (visual acuity 6/60 and worse). The initial visual acuity was more in closed globe than open globe injuries.

Patients with posterior segment involvement in the study group had poorer visual outcome. Posterior segment findings include Retinal detachment in 36 eyes, vitreous hemorrhage in 23 eyes, macular hole in 17 eyes, traumatic optic neuropathy in 8 eyes. In the current series 12 eyes has poor vision because of retinal and optic nerve involvement. This is consistent with other studies [37-38].

"In addition to visual impairment, ocular injuries cause psychosocial stress, and increased economic burden. Work related injuries cause a huge amount of economic burden to an estimated at 1 to 3 billion dollars annually" [39].

There is a need to develop preventive strategies including health education of general population to prevent visual impairment due to trauma. Our study indicates a significant burden of ocular trauma in the state of Jharkhand, which has not been reported earlier. Even after treatment by an ophthalmologist, final visual outcome is not significantly influenced, thus making it imperative



that preventive eye care programs consider ocular trauma in the population as a priority.

## 5. CONCLUSION

A comprehensive study of various types of ocular injuries, their management, subsequent complications and prognosis has been undertaken from the 948 cases of ocular injury attending Ophthalmology Department of RIO, RIMS, Ranchi. The visual outcome depends upon the site, size and type of injury, duration between the time of injury and seeking treatment. The school children playing with sharp objects like pencils, sticks, etc. are mainly prone to the injury as they are not aware of consequences out of ignorance. Ocular injury can occur at any age, but is more common in young males. Most of the ocular injuries occurred in workplace, industries and among laborers and road traffic accidents. There is a need for strict reinforcement of traffic rules and industrial safety protocols. Though prevention of assault related eye injuries is more difficult than work and sport related eye injuries. The public must be made aware of dangers of driving under influence of alcohol. The incidence of ocular trauma can be decreased by the proper use of safety devices like protective goggles or shields, face masks etc. during work. The counseling of farmers regarding the usage of protective glasses at work and the education of parents and teachers regarding the prevention of ocular injuries in children may go a long way in reducing the visual morbidity from ocular trauma.

## DISCLAIMER (ARTIFICIAL INTELLIGENCE)

NO generative AI technologies such as Large Language Models (ChatGPT, COPILOT, etc) and text-to-image generators have been used during writing or editing of manuscripts.

## CONSENT

As per international standards or university standards, patient(s) written consent has been collected and preserved by the author(s).

## ETHICAL APPROVAL

As per international standards or university standards written ethical approval has been collected and preserved by the author(s).

## COMPETING INTERESTS

Authors have declared that no competing interests exist.

## REFERENCES

1. Editorial progress in Surgical Management of Ocular trauma. *British J. Ophthalmology*. 1976;60:731.
2. Desai P, MacEwen CJ, Baines P, Minassain DC. Incidence of cases of ocular trauma admitted to hospital and incidence of blinding outcome. *British J. Ophthalmology*. 1976;80:592-6.
3. Nagrel AD, Thylefors B. The global impact of eye injuries [J]. *Ophthalmic Epidemiol*. 1998;5:143-69.
4. Vats S, Murthy GV, Chandra M, Gupta SK, Vashist P, Gogoi M. Epidemiological study of ocular trauma in an urban slum population in Delhi, India. *Indian J Ophthalmol*. 2008;56:313-6.
5. Thompson CG, Kumar N, Billson FA, et al. The aetiology of perforating ocular injuries in children. *British J. Ophthalmology*. 2002;86:920-2.  
Vats S, Murthy GVS, Chandra M, Gupta SK, Vashist P, et al. Epidemiological study of ocular trauma in an urban slum population in Delhi, India. *Indian J Ophthalmol*. 2008;56:313-316
6. Khatry SK, Lew is AE, Sche OD, Thapa MD, Pradhan EK, et al. The epidemiology of ocular trauma in rural Nepal. *Br J Ophthalmol*. 2004;88:456-460.
7. Parmar NRC, Sunandan S. Pattern of ocular injuries in Haryana. *Ind J Ophthalmol*. 1985;33:141-14.
8. Narang S, Gupta V, Simalandhi P, Gupta A, Raj S, Dogra MR. Paediatric open globe injuries. Visual outcome and risk factors for endophthalmitis. *Ind J Ophthalmol*. 2004; 52(1):29-34.
9. Kuhn F, Morris R, Witherspoon CD. Birmingham Eye Trauma Terminology (BETT): Terminology and classification of mechanical eye injuries. *Ophthalmol Clin N Am*. 2002;15:139-43.
10. Cillino S, Casuccio A, Di Pace F, Pillitteri F, Cillino G. A Five-year retrospective study of epidemiological characteristics and visual outcomes of patients hospitalized for ocular trauma in Mediterranean area. *BMC Ophthalmology*. 2008;22:6.

11. Guly CM, Guly HR, Bouamra O, Gray RH, Lecky FE. Ocular injuries in patients with major trauma. *Emerg. Med. J.* 2006; 23:915-7.
12. Glynn RJ, Seddon JM, Berlin BM. The incidence of eye injuries in New England. *Arch Ophthalmol.* 1988;106:785-789.
13. Macewen CJ. Ocular injuries. *J R Coll Surg Edinb.* 1999;44:317-2
14. Dandona L, Dandona R, Srinivas M, John RK, McCarty CA, Rao GN. Ocular trauma in an urban population in Southern India: The Andhra Pradesh eye disease study. *Clin. Exp. Ophthalmol.* 2000, Oct;28(5): 350-6.
15. Babar TF, Khan MT, Marwat MZ, Shah SA, Murad Y, Khan MD. Patterns of ocular trauma. *JCPSP.* 2007;17:148-53.10.
16. Jahangir T, Butt NH, Hamza U, et al. Pattern of presentation and factors leading to ocular trauma. *Pak J Ophthalmol.* 2011; 27:96-102. 11.
17. Arfat MY, Butt HM. Visual outcome after anterior segment trauma of the eye. *Pak J Ophthalmol.* 2010;26:74-7.
18. Govind ST, Pandey S, Sharma V. An unusual presentation of neglected naso-orbital foreign body. *Jemds.* 2013;2:3717-19. 3.
19. Vats S, Murthy GVS, Chandra M, et al. Epidemiological study of ocular trauma in an urban slum population in Delhi, India. *Indian J Ophthalmol.* 2008;56(4):313-16. 4.
20. Prakash DN, Sathish K et al, Study of demographic and clinical profile of ocular trauma. *Journal of Evolution of Medical and Dental Sciences.* 2013, March;2(11):1741- 1746.
21. Gyasi ME, Amoaku WMK, Adjuik MA. Epidemiology of hospitalized ocular injuries in the upper east region of Ghana. *Ghana Medical Journal.* 2007;4194:171-5. 22.
22. Schein OD, Hibberd PL, Shingleton BJ, Kunzweiler T, Frambach DA, Seddon JM, Fontan NL, Vinger PF. The spectrum and burden of ocular injury. *Ophthalmology.* 1988;95:300. 23.
23. Oum BS, Lee JS, Han YS. Clinical Features of Ocular Trauma in Emergency Department Korean *J Ophthalmol.* 2004; 18:70-78.
24. Sony Sinha et al, Pattern of trauma to anterior segment of eyes in a tertiary eye care centre of Jharkhand, *Journal of the Indian Medical Association,* 06. 2008; 106(5):289-90
25. Nirmalan PK, Katz J, Tielsch JM, Robin AL, Thulasirj RD, Krishnadas R, et al. Ocular trauma in a rural South Indian population: Aravind Comprehensive Eye Survey. *Ophthalmol.* 2004;111:1778-81.
26. Krishnaiah, Thomas, Ravi et al. Ocular trauma in rural Population of Southern India: The Andhra Pradesh eye disease study *ophthalmology.* 2006;113(7):1159-1164.
27. Rajendra P Maurya, Tanmay Srivastav, Virendra Pratap Singh, Mishra CP, Abdullah Al-Mujaini. The epidemiology of ocular trauma in Northern India: A teaching hospital study *Oman J Ophthalmol.* 2019, May-Aug;12(2):78–83.
28. Umesh RE, Umesh OC. Causes and visual outcome of childhood eye injuries in Nigeria. *Eye.* 1997;11:489-95.
29. Krishnan MM, Srinivasan R. Ocular injuries in Union Territory of Pondicherry- visual outcome. *Indian J Ophthalmol.* 1988;36: 82-85.
30. Bigar F. Primary wound closure after eye injuries. An analysis of 100 cases. *Klin Monatsbl Augenheilkd.* 1981;178(4):299-302.
31. Ariturk N, Sahin M, Oge L, Erkan D, Sallu Y. The evaluation of ocular trauma in children between ages 0-12. *Turk J Pediatr.* 1999;41:43-52.
32. MacEwen CJ, Baines PS, Desai P. Eye injuries in children: The current picture. *Br. J. Ophthal.* 1990;83:933-6.
33. Jahangir T, Butt NH, Hamza U, et al. Pattern of presentation and factors leading to ocular trauma. *Pak J Ophthalmol.* 2011;27:96-102.
34. Fasih U, Shaikh A, Fehmi MS. Occupational ocular trauma (causes, Management and prevention). *Pak J Ophthalmol.* 2004;20:65-73.
35. Omolase CO1, Omolade EO, Ogunleye OT, Omolase BO, Ihemedu CO, Adeosun OA. Pattern of ocular injuries in owo, Nigeria. *J Ophthalmic Vis Res.* 2011;6 2):114-118.
36. Cillino S, Casuccio A, Pace FD, Pillitteri F, Cillino G. A five-year retrospective study of the epidemiological characteristics and visual outcomes of patients hospitalized for ocular trauma in a Mediterranean area. *BMC Ophthalmology.* 2008;8:6. DOI:10.1186/1471-2415-8-6
37. McCarty CA, Fu CL, Taylor HR. Epidemiology of ocular trauma in Australia. *Ophthalmology.* 1999;106:1847–1852

38. Rahman I, Maino A, Devadason D, Leatherbarrow B. Open globe injuries: Factors predictive of poor outcome. Eye. 2006;20(12):1336–1341.
39. Omolase CO1, Omolade EO, Ogunleye OT, Omolase BO, Ihemedu CO, Adeosun OA. Journal of Ophthalmic & Vision Research, 01 Apr 2011, 6(2):114-118

**Disclaimer/Publisher's Note:** The statements, opinions and data contained in all publications are solely those of the individual author(s) and contributor(s) and not of the publisher and/or the editor(s). This publisher and/or the editor(s) disclaim responsibility for any injury to people or property resulting from any ideas, methods, instructions or products referred to in the content.

© Copyright (2024): Author(s). The licensee is the journal publisher. This is an Open Access article distributed under the terms of the Creative Commons Attribution License (<http://creativecommons.org/licenses/by/4.0>), which permits unrestricted use, distribution, and reproduction in any medium, provided the original work is properly cited.

*Peer-review history:*  
*The peer review history for this paper can be accessed here:*  
<https://www.sdiarticle5.com/review-history/119691>